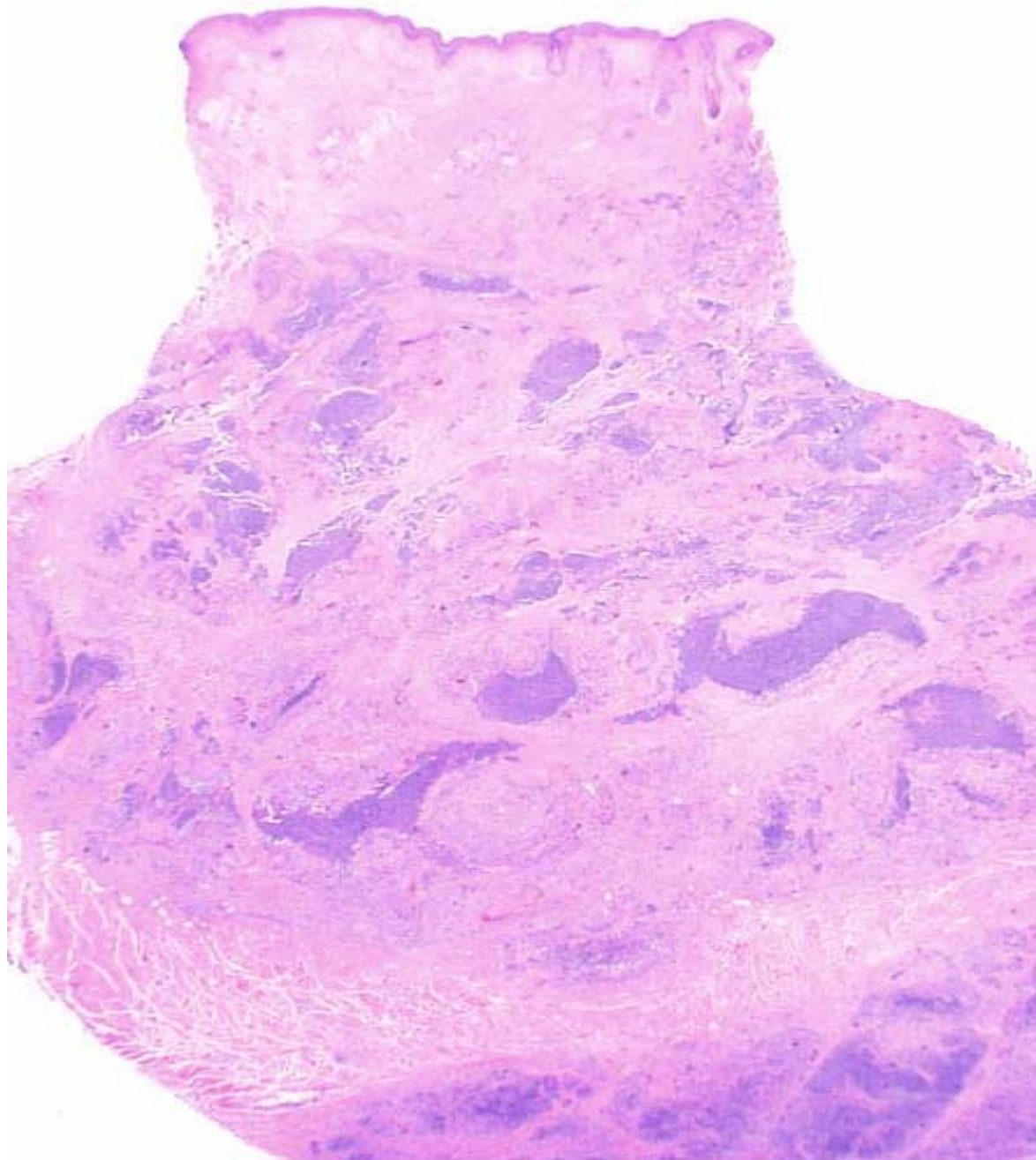


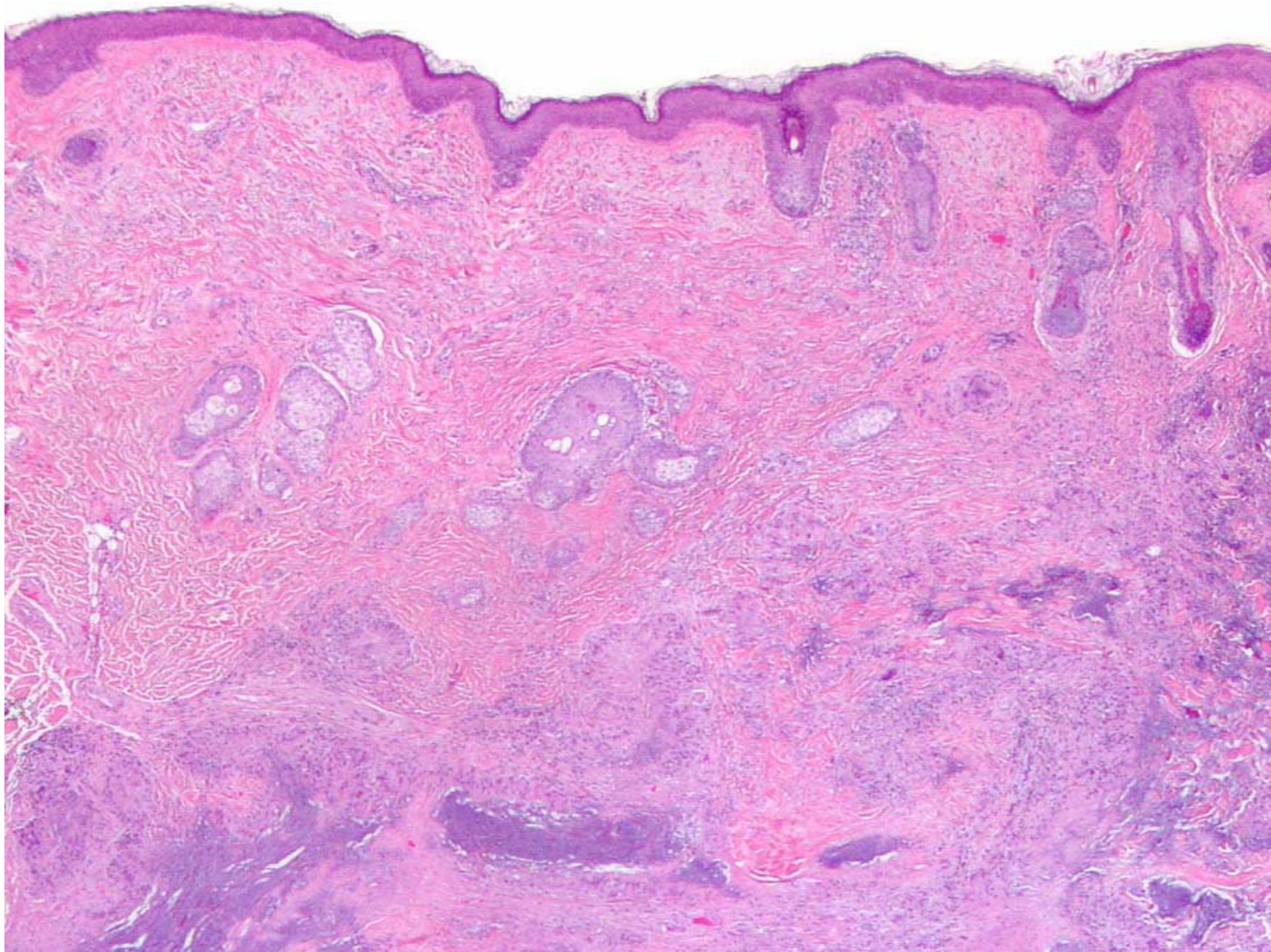
## ***Clinical Information:***

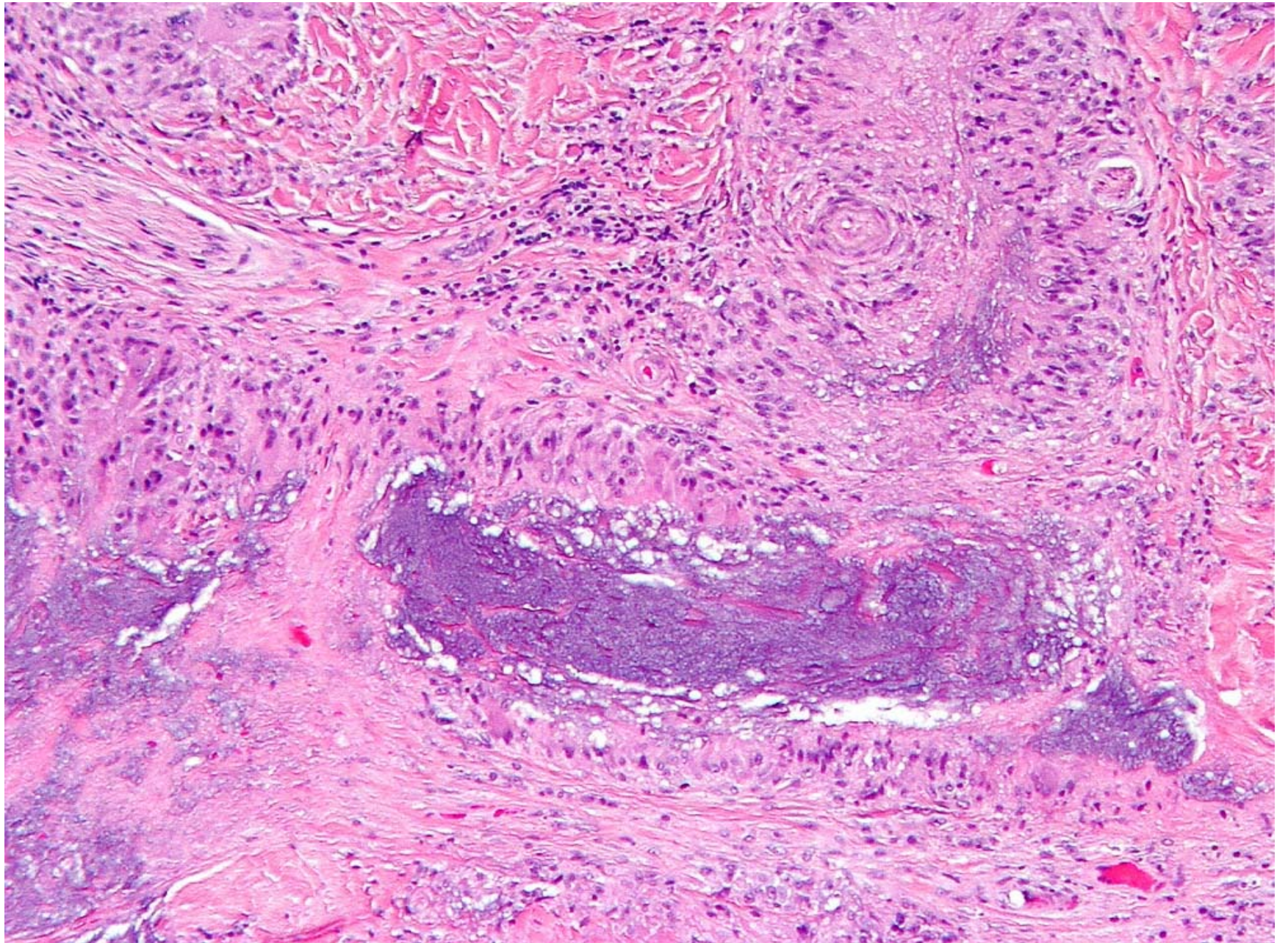
74 year-old Hispanic female with “infiltrative friable process involving corrugator muscle and skin” of glabella and nose

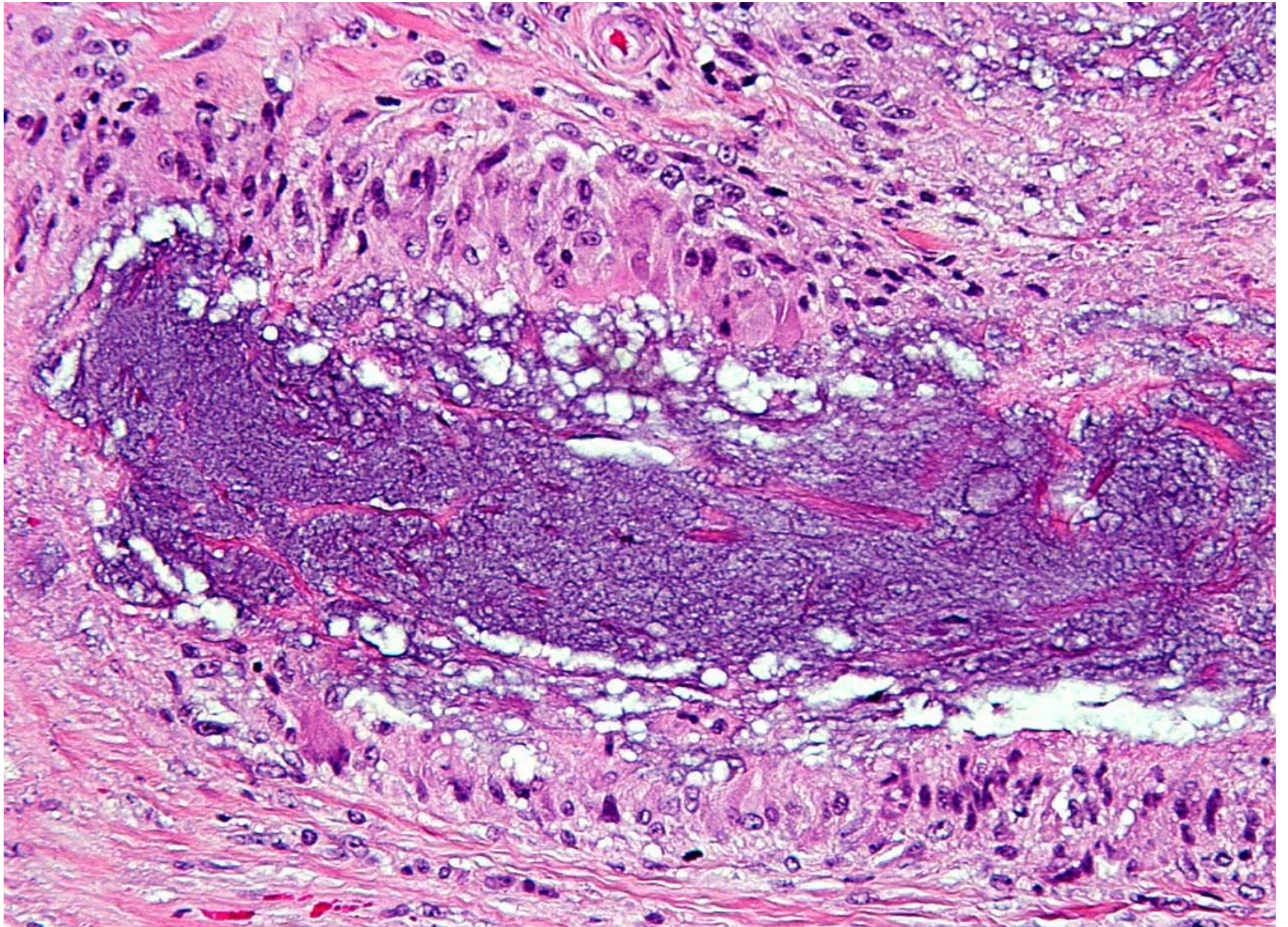
Past Clinical History: rhinoplasty 30 years ago and cosmetic eye surgery ? years ago outside the United States

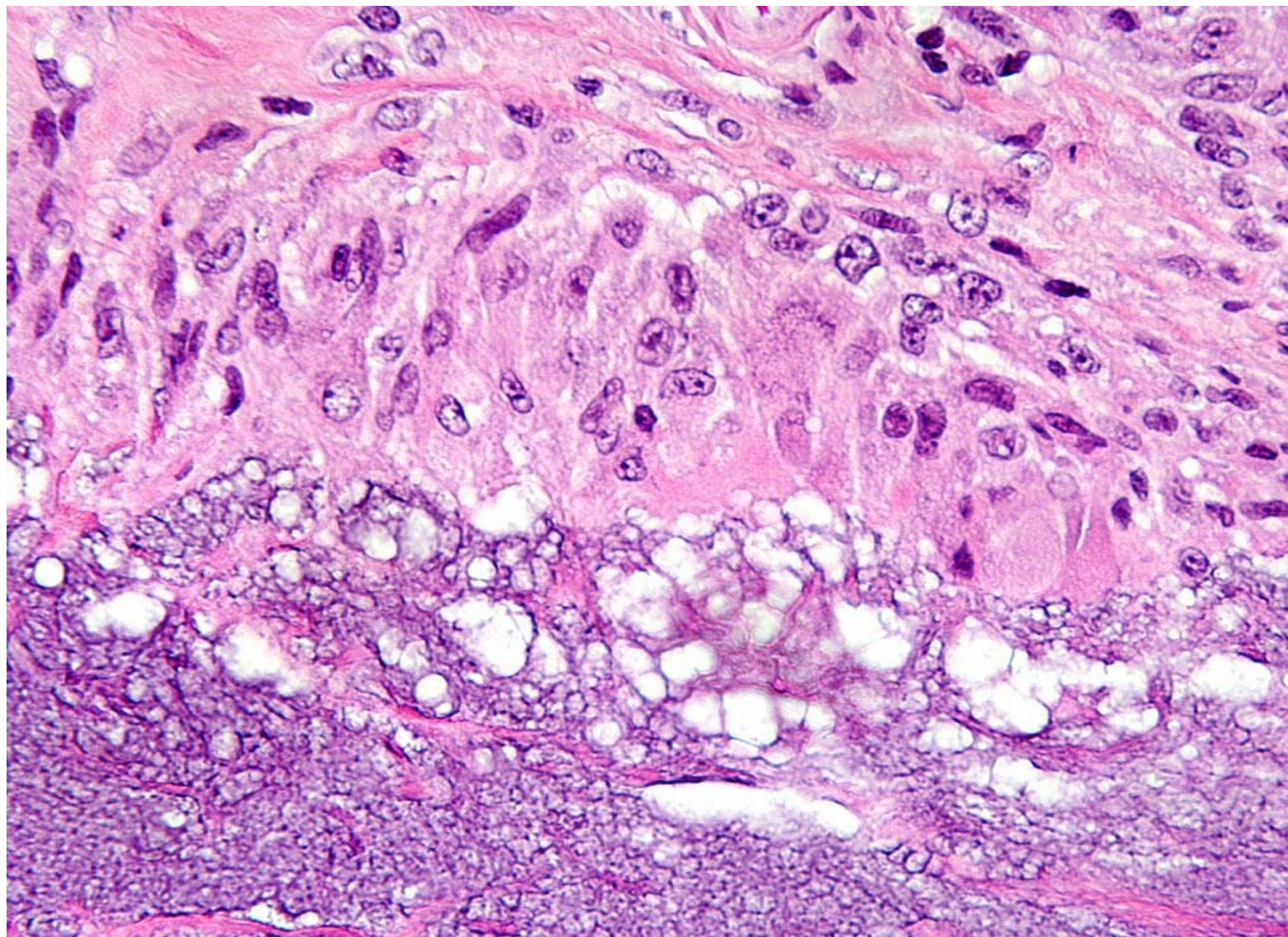
No clear history of injection

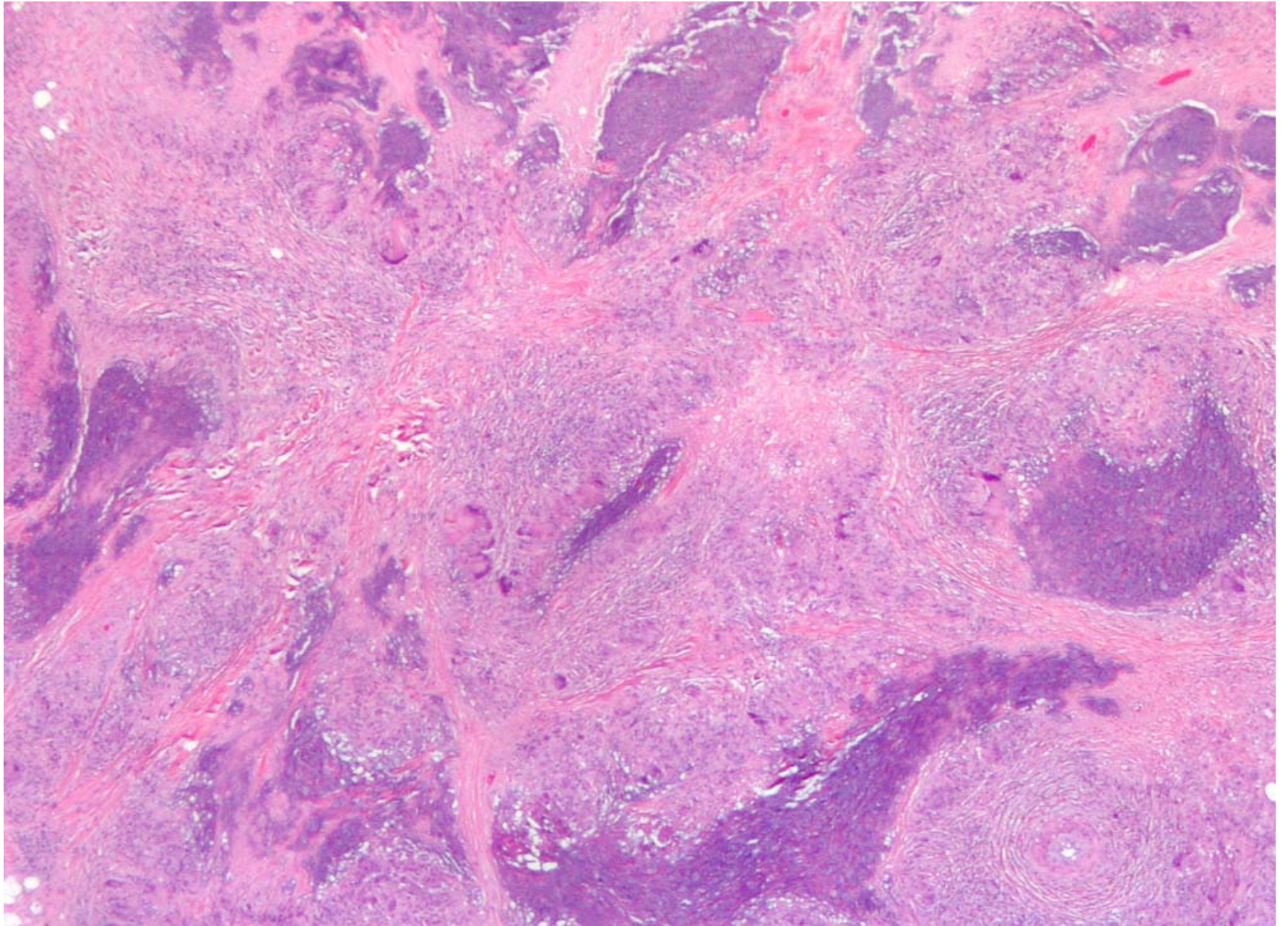


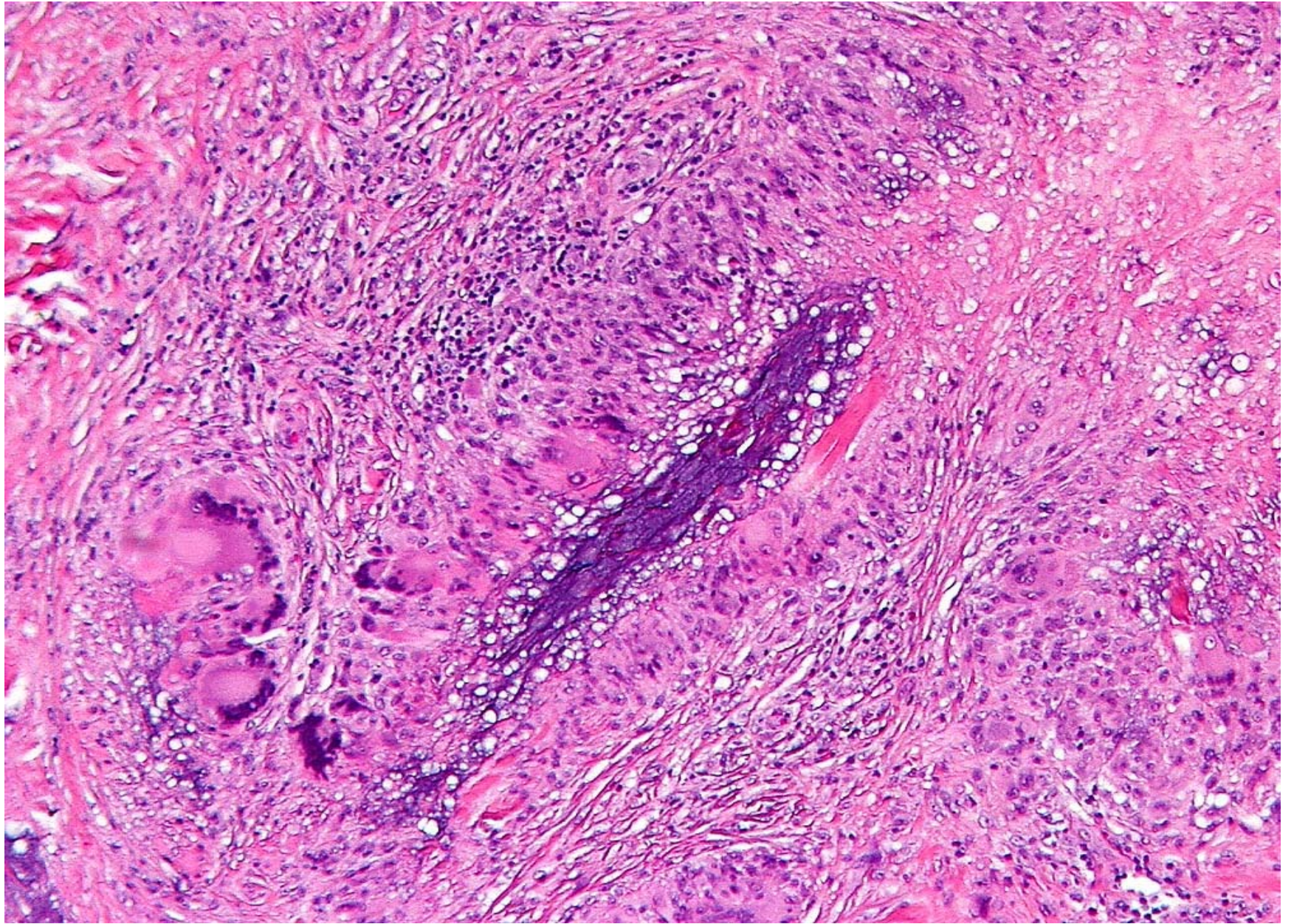


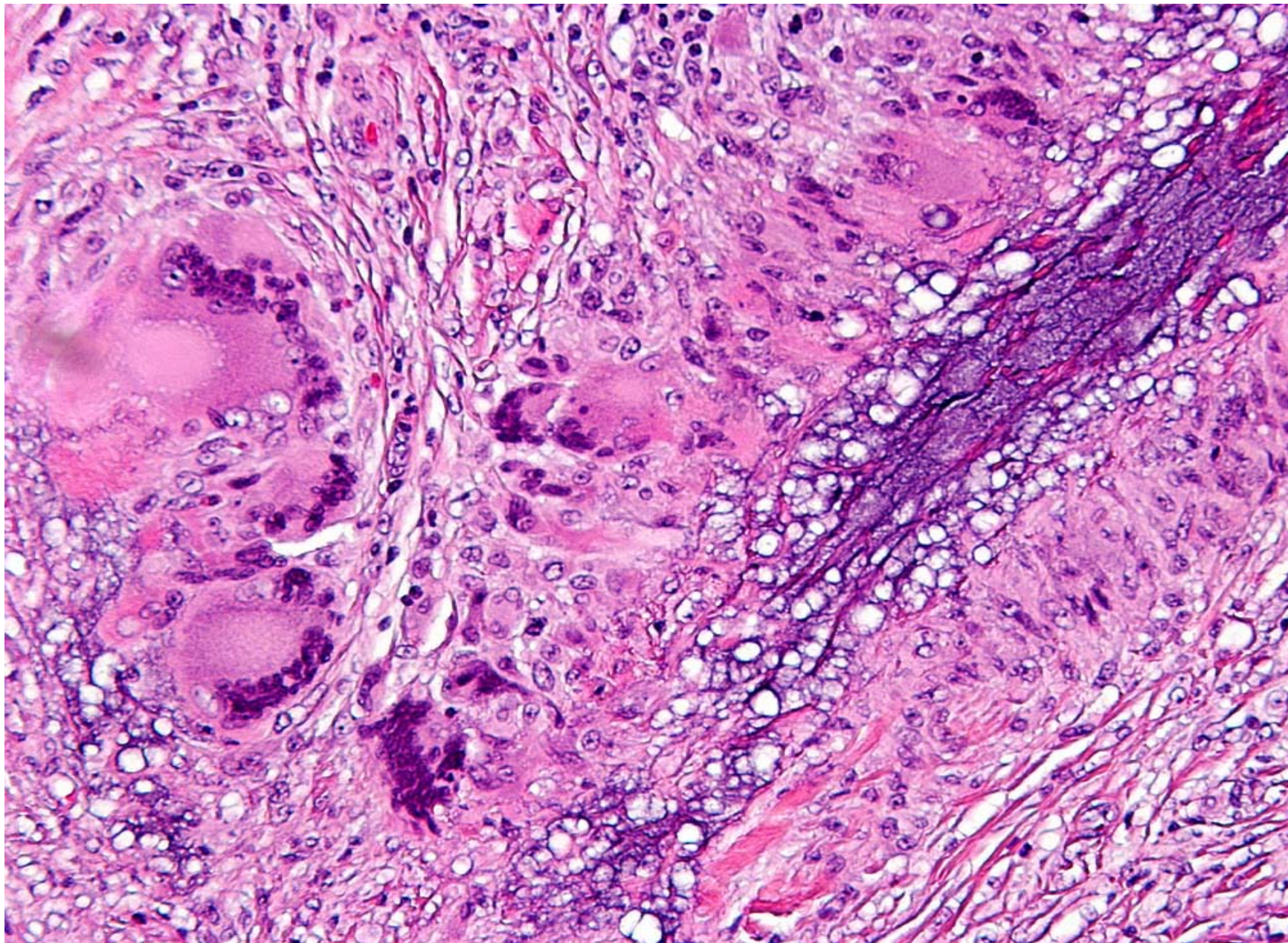


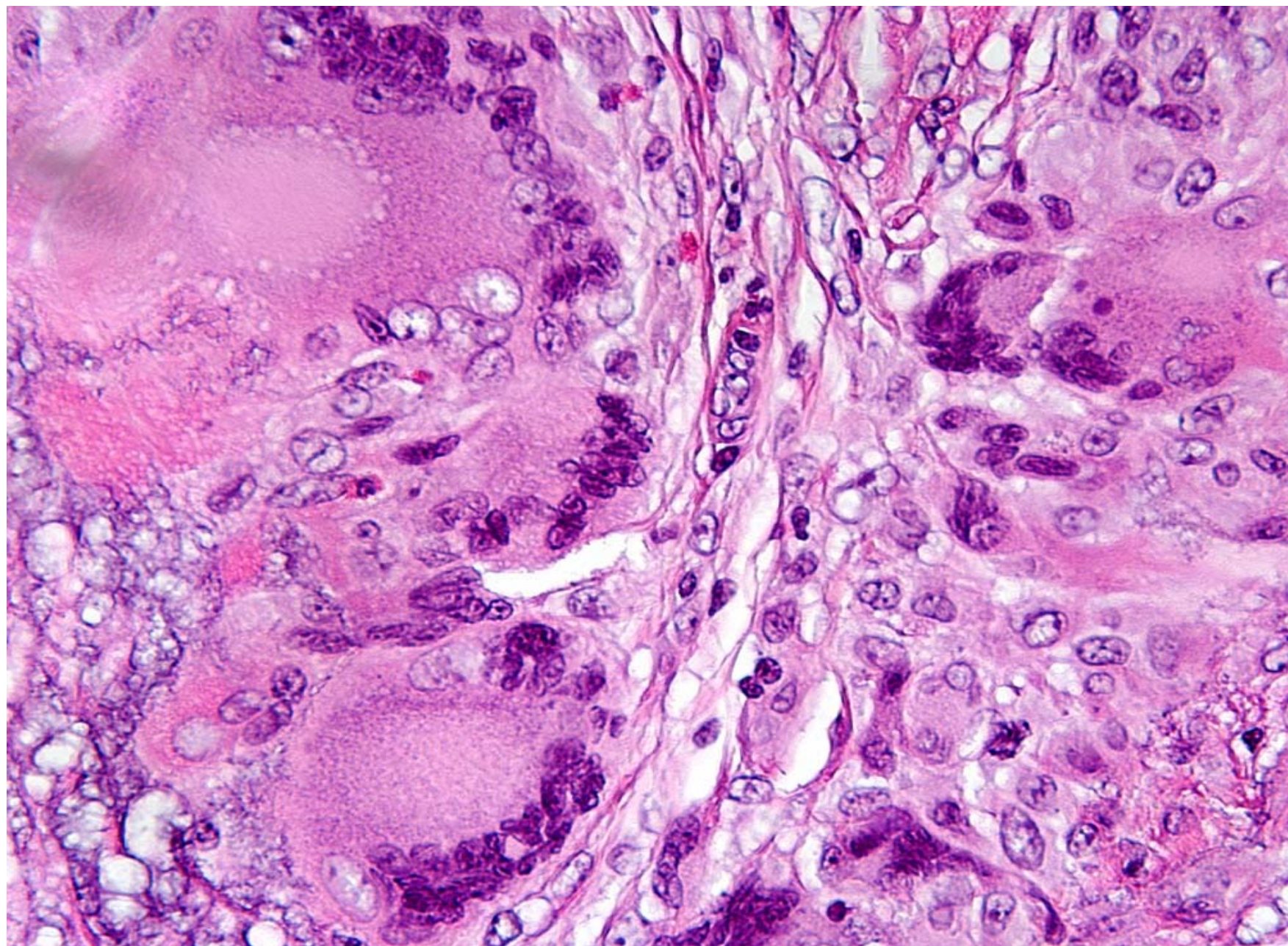


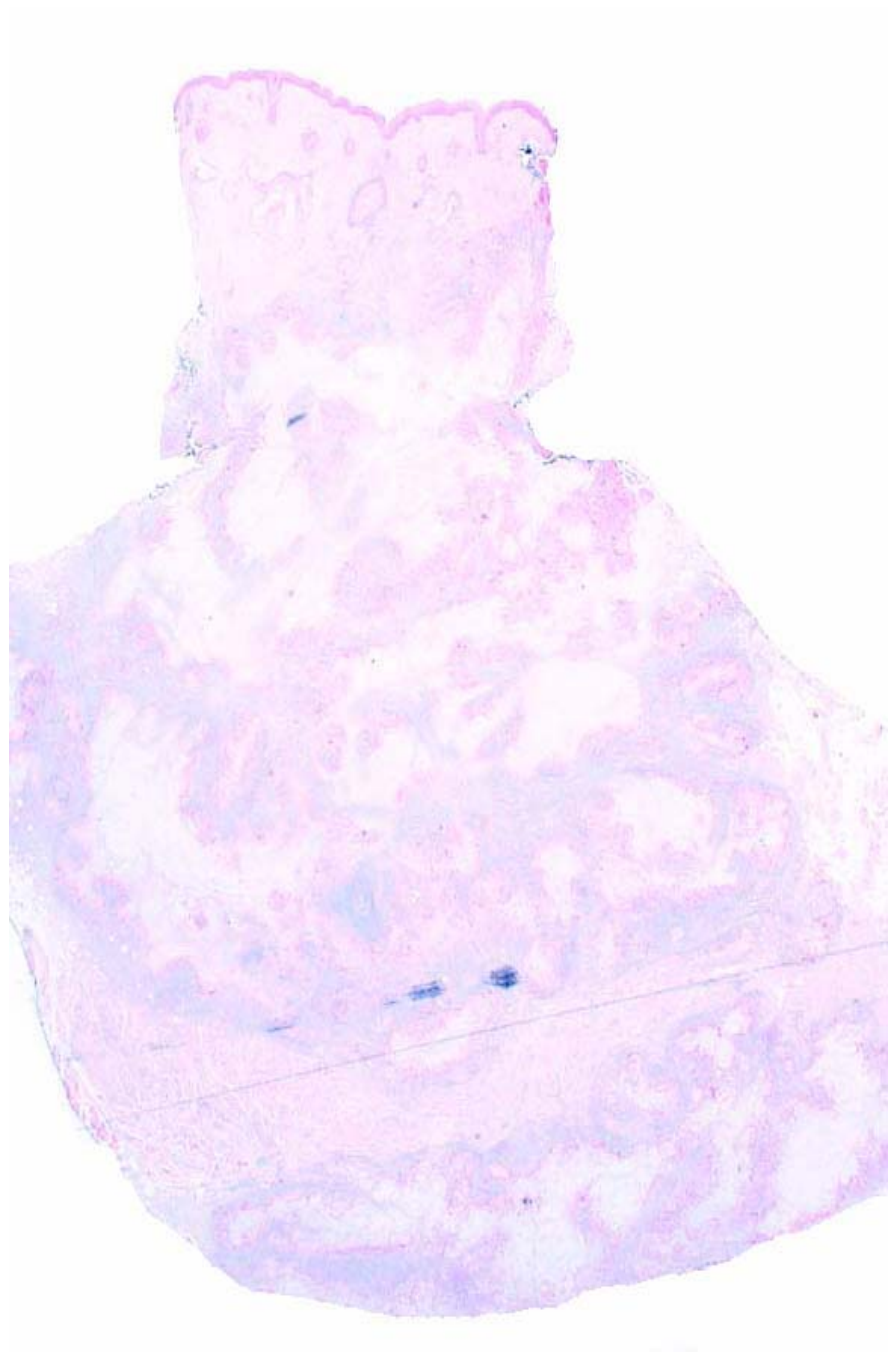


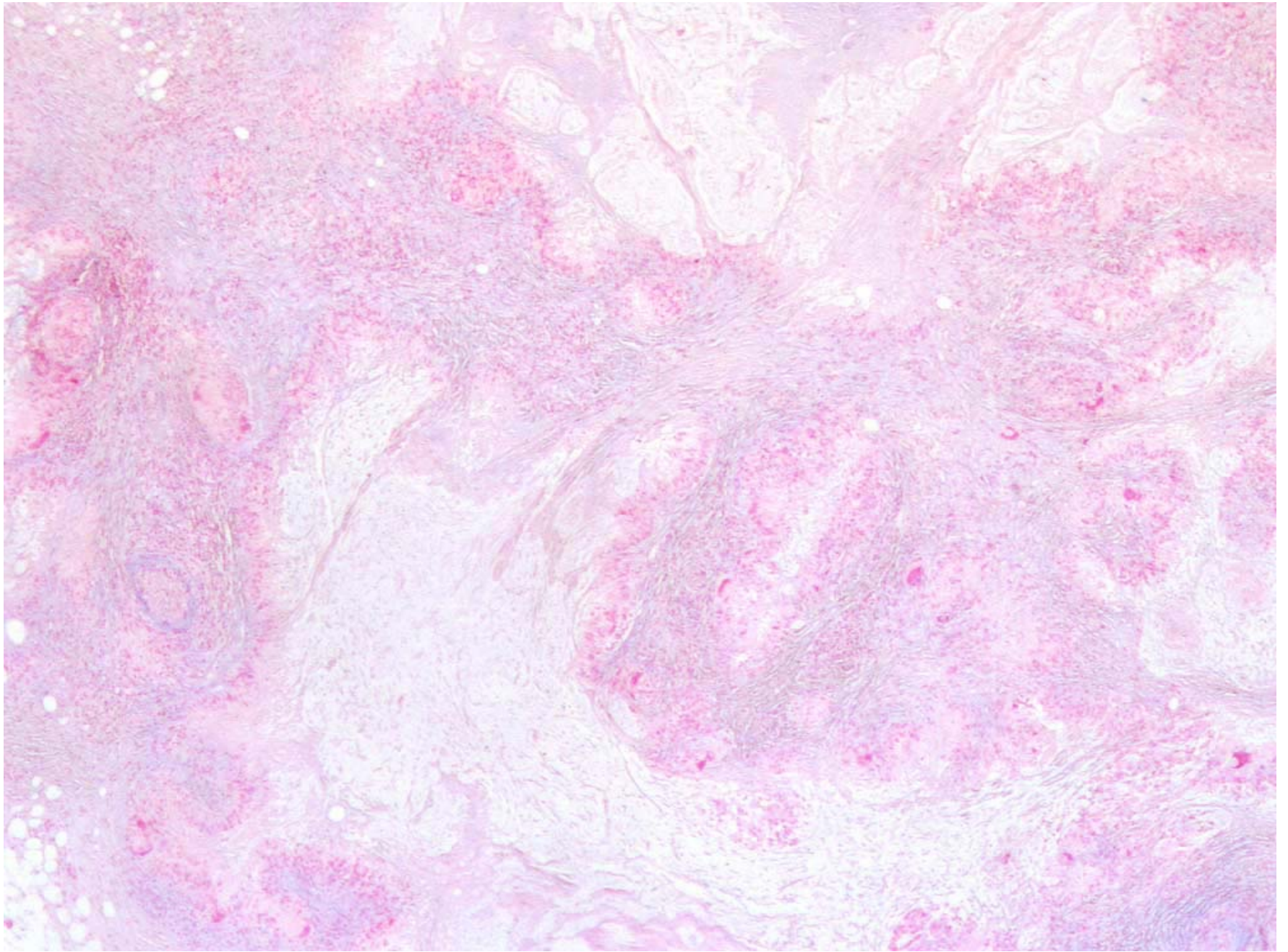












*Diagnosis:*

*Foreign Body Granuloma*